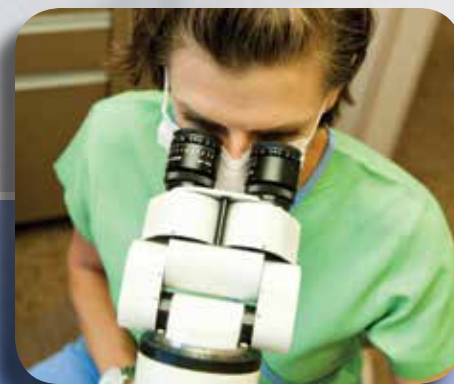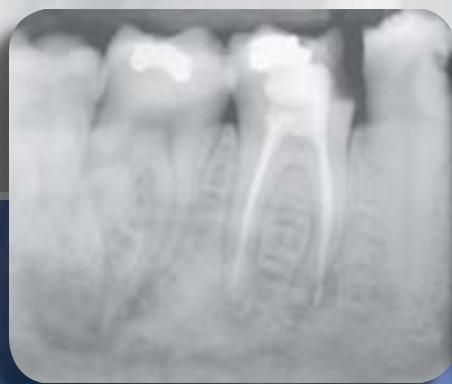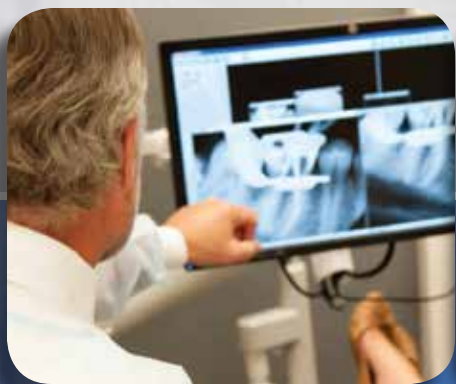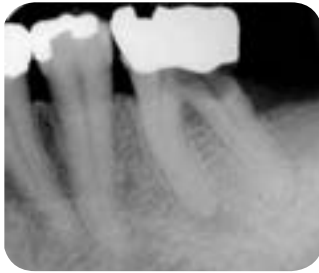


# Treatment Options for the Compromised Tooth: *A Decision Guide*

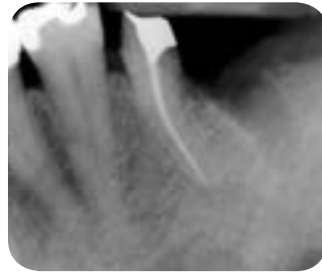

## Case One

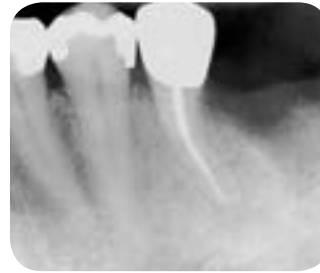Hemisection of the distal root of tooth #19.



PreOp




PostOp



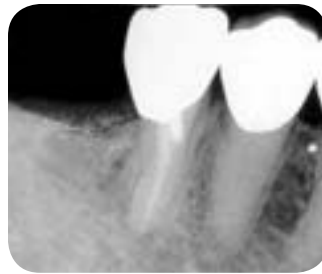13 mo. Recall

## Case Two\*

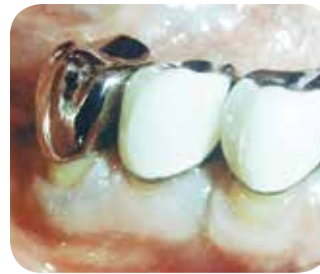Hemisection of the distal root of tooth #30.



PreOp



PostOp



Clinical Photograph

*\* These images were published in The Color Atlas of Endodontics, Dr. William T. Johnson, p. 162, Copyright Elsevier 2002.*

### TREATMENT CONSIDERATIONS/PROGNOSIS > Remaining Coronal Tooth Structure

#### FAVORABLE:

- Greater than 1.5 mm ferrule

#### QUESTIONABLE:

- 1.0 to 1.5 mm ferrule

#### UNFAVORABLE:

- Less than 1 mm ferrule

### TREATMENT CONSIDERATIONS/PROGNOSIS > Crown Lengthening

#### FAVORABLE:

- None needed

#### QUESTIONABLE:

- If required will not compromise the aesthetics or periodontal condition of adjacent teeth

#### UNFAVORABLE:

- Treatment required that will affect the aesthetics or further compromise the osseous tissues (support) of the adjacent teeth

### TREATMENT CONSIDERATIONS/PROGNOSIS > Endodontic Treatment

#### FAVORABLE:

- Routine endodontic treatment or not required due to previous treatment

#### QUESTIONABLE:

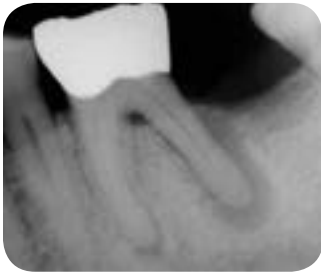- Nonsurgical root canal retreatment required prior to root resection

#### UNFAVORABLE:

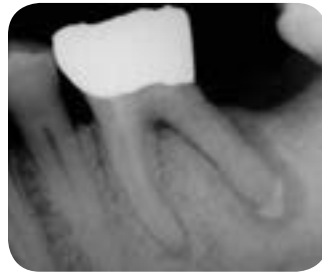
- Canal calcification, complex canal and root morphology, and isolation complicate an ideal endodontic treatment result

**Case One**

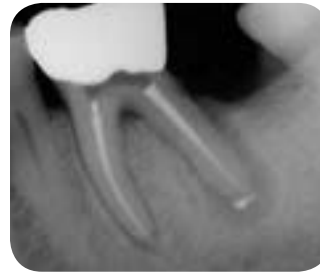
Tooth #19 exhibiting probing to the distal apex. Treated in two steps using interim calcium hydroxide.



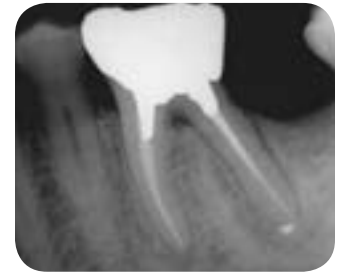PreOp



Calcium Hydroxide



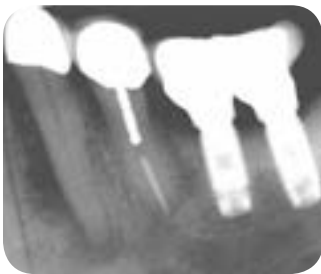
PostOp



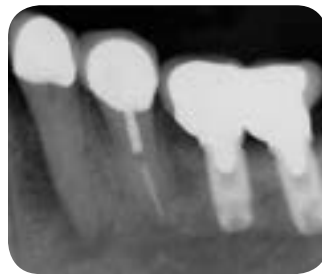
12 mo. Recall

**Case Two**

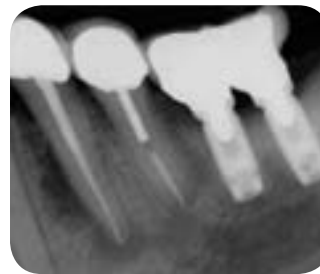Tooth #21 exhibiting a wide, but deep probing on the mesial aspect. Treated in two steps using interim calcium hydroxide.



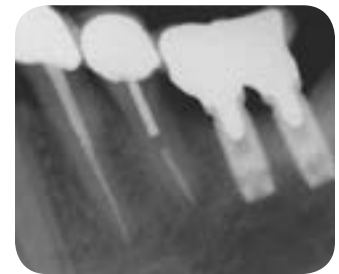
PreOp



Calcium Hydroxide



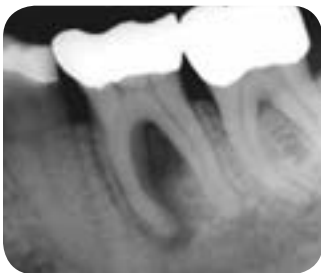PostOp



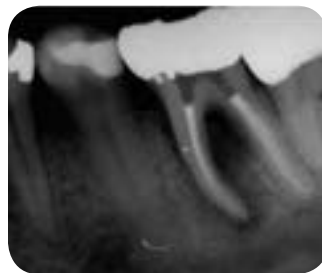12 mo. Recall

**Case Three**

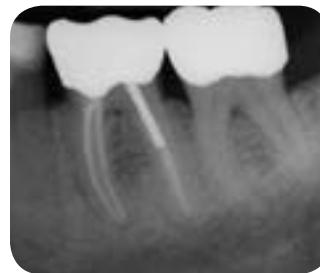Tooth #19 with an 8 mm probing into furcation. Interim calcium hydroxide used.



PreOp



PostOp



12 mo. Recall

TREATMENT CONSIDERATIONS/PROGNOSIS > **Periodontal Conditions**

**FAVORABLE:**

- Normal periodontium
- Normal probing depths (3 mm or less)
- The tooth exhibits pulp necrosis and isolated bone loss to the involved tooth or root

**QUESTIONABLE:**

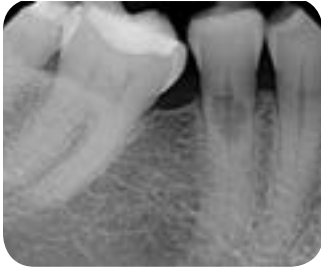- Moderate periodontal disease
- An isolated periodontal probing defect
- The tooth exhibits pulp necrosis and moderate bone loss

**UNFAVORABLE:**

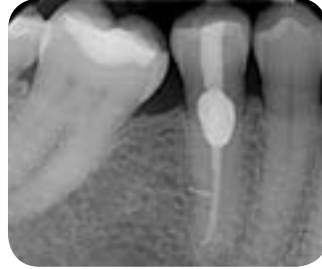- Advanced periodontal disease
- Generalized periodontal probing defects throughout the patient's mouth
- The tooth exhibits pulp necrosis and there is generalized bone loss (horizontal and/or vertical)

**Case One**

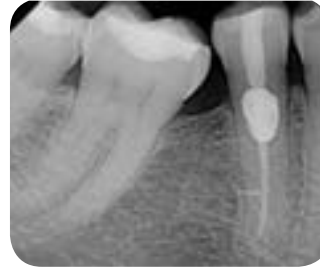External resorptive defect on buccal aspect of tooth #29. Mineral trioxide aggregate (MTA) placed in the coronal 6 mm of canal and surgical repair with Geristore.<sup>®</sup>



PreOp



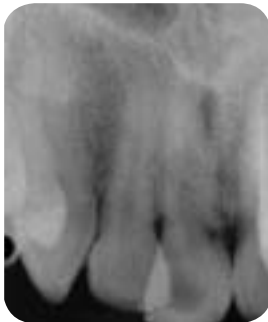PostOp



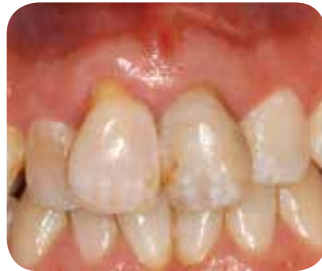27 mo. Recall

**Case Two**

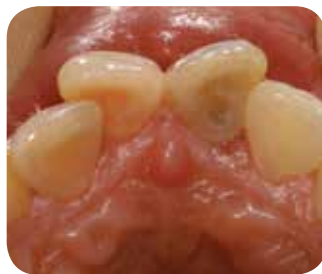Tooth #8 questionable prognosis; external resorption on the mesial with a periodontal probing defect on the mesiopalatal.



PreOp



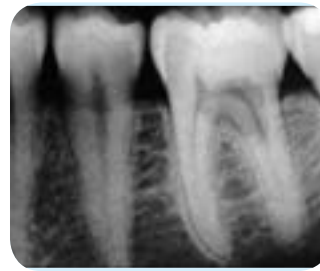Facial View



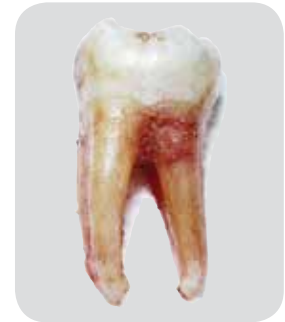
Lingual View

**Case Three**

Tooth #19 unfavorable prognosis; there is a large cervical resorptive defect on the buccal aspect of the distal root extending into the furcation.



PreOp



Clinical Photograph

TREATMENT CONSIDERATIONS/PROGNOSIS > **External Resorption**

**FAVORABLE:**

- Minimal loss of tooth structure
- Located cervically but above the crestal bone
- The lesion is accessible for repair
- Apical root resorption associated with a tooth exhibiting pulp necrosis and apical pathosis

**QUESTIONABLE:**

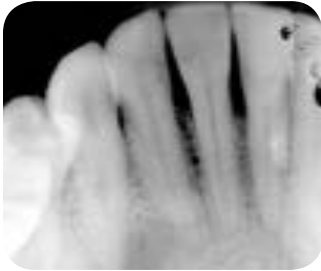- Minimal impact on restorability of tooth
- Crown lengthening or orthodontic root extrusion may be required
- The pulp may be vital or necrotic

**UNFAVORABLE:**

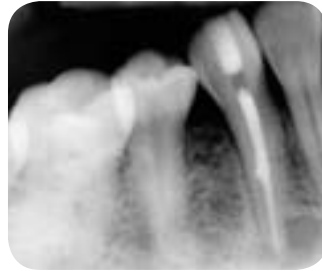- Structural integrity of the tooth or root is compromised
- There are deep probing depths associated with the resorptive defect
- The defect is not accessible for repair surgically

**Case One**

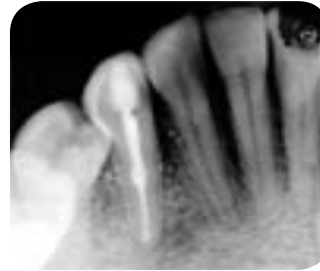Tooth #28 exhibiting a mid-root internal resorptive defect.



PreOp



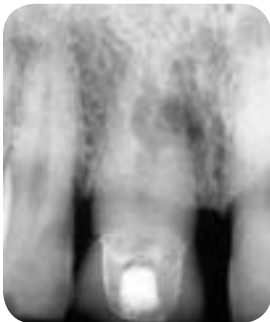PostOp



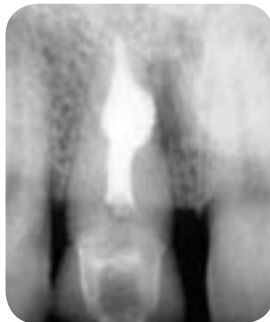14 mo. Recall

**Case Two**

Tooth #8 exhibiting an apical to mid-root internal resorptive lesion.



PreOp



PostOp

TREATMENT CONSIDERATIONS/PROGNOSIS > **Internal Resorption**

**FAVORABLE:**

- Small/medium defect
- A small lesion in the apical or mid-root area

**QUESTIONABLE:**

- Larger defect that does not perforate the root

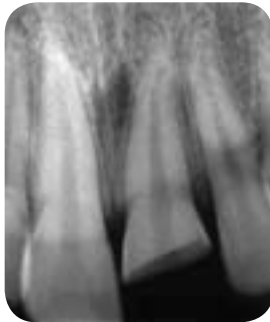**UNFAVORABLE:**

- A large defect that perforates the external root surface

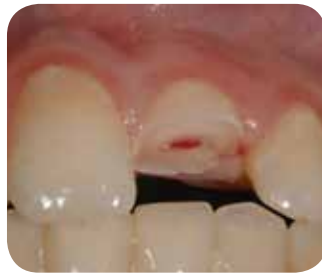

**Crown Fracture**

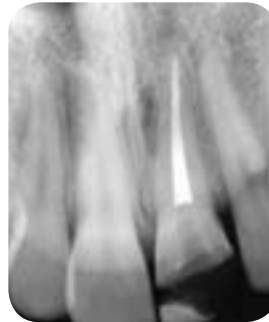Tooth #8 exhibiting a complicated coronal fracture, root canal treatment and bonding of the coronal segment.



PreOp



Clinical Photograph



PostOp

TREATMENT CONSIDERATIONS/PROGNOSIS > **Crown Fractures**

**FAVORABLE:**

- Coronal fracture of enamel or dentin not exposing the pulp
- Coronal fracture of enamel and dentin exposing the pulp of a tooth with mature root development

**QUESTIONABLE:**

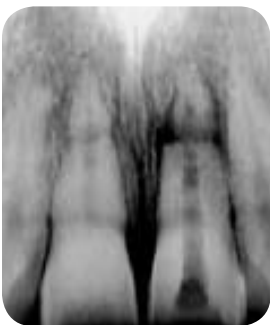- Coronal fracture of enamel and dentin exposing the pulp with immature root development

**UNFAVORABLE:**

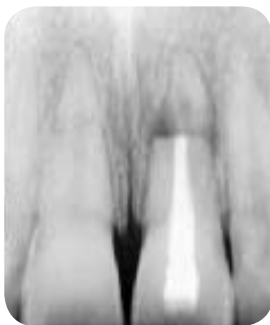- Coronal fracture of enamel or enamel and dentin extending onto the root below the crestal bone
- Compromised restorability requiring crown lengthening or orthodontic root extrusion

**Horizontal Root Fracture\***

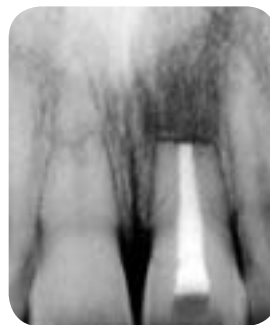Horizontal root fractures of #8 and #9; the maxillary right central remained vital while the maxillary left central developed pulp necrosis requiring nonsurgical and surgical root canal treatment; prognosis favorable.



PreOp



RCT PostOp



Surgical PostOp

*\* These images were published in The Color Atlas of Endodontics, Dr. William T. Johnson, p. 176, Copyright Elsevier 2002.*

TREATMENT CONSIDERATIONS/PROGNOSIS > **Horizontal Root Fractures**

**FAVORABLE:**

- The fracture is located in the apical or middle third of the root
- There is no mobility
- The pulp is vital (note in the majority of root fractures the pulp retains vitality)

**QUESTIONABLE:**

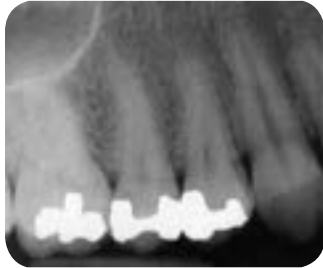- The fracture is located in the coronal portion of the root and the coronal segment is mobile
- There is no probing defect
- The pulp is necrotic
- A radiolucent area is noted at the fracture site

**UNFAVORABLE:**

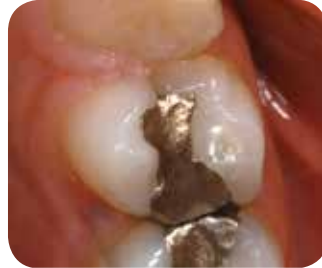- The fracture is located in the coronal portion of the root and the coronal segment is mobile
- There is sulcular communication and a probing defect

**Case One**

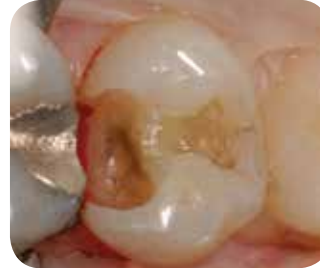Fracture of the mesial marginal ridge of tooth #5, stopping coronal to pulp floor.



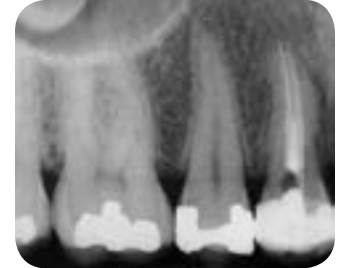PreOp



Mesial Crack



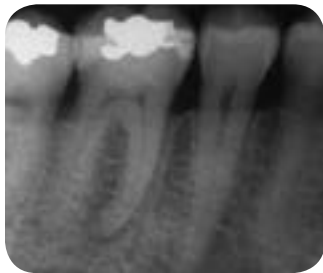Internal Crack



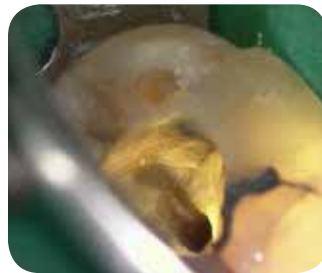PostOp

**Case Two**

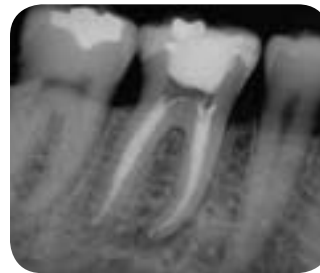Tooth #30 exhibiting pulp necrosis and asymptomatic apical periodontitis; a crack was noted on the distal aspect of the pulp chamber under the composite during root canal treatment.



PreOp

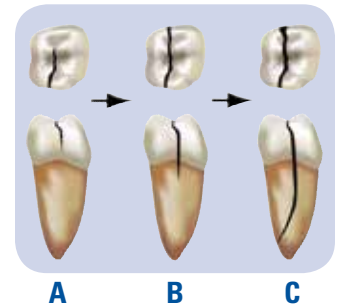


Distal Crack



PostOp

**Cracked Tooth Progression To Split Tooth\***



- A** Favorable prognosis
- B** Questionable prognosis
- C** Split tooth, Unfavorable prognosis

\* Reprinted with permission from Torabinejad and Walton, Endodontics: Principles and Practice 4th ed, Saunders/Elsevier 2009.

TREATMENT CONSIDERATIONS/PROGNOSIS > **Cracked Tooth**

**FAVORABLE:**

- Fracture in enamel only (crack line) or fracture in enamel and dentin
- The fracture line does not extend apical to the cemento-enamel junction
- There is no associated periodontal probing defect

- The pulp may be vital requiring only a crown
- If pulp has irreversible pulpitis or necrosis, root canal treatment is indicated before the crown is placed

**QUESTIONABLE:**

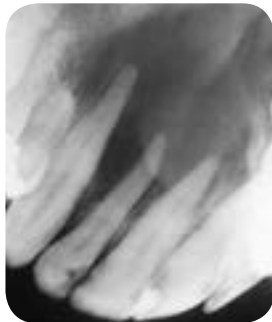- Fracture in enamel and dentin
- The fracture line may extend apical to the cemento-enamel junction but there is no associated periodontal probing defect
- There is an osseous lesion of endodontic origin

**UNFAVORABLE:**

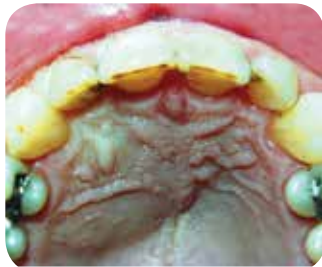- Fracture line extends apical to the cemento-enamel junction extending onto the root with an associated probing defect

**Case One**

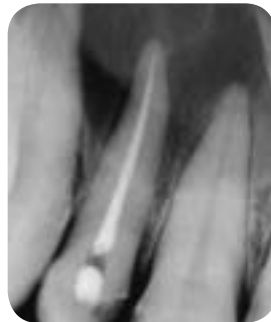A large periapical lesion resulting in an acute apical abscess from pulp necrosis of tooth #7.



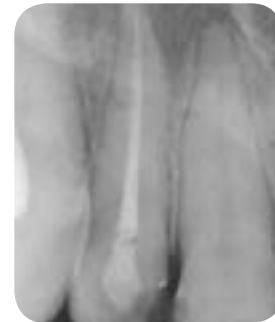PreOp



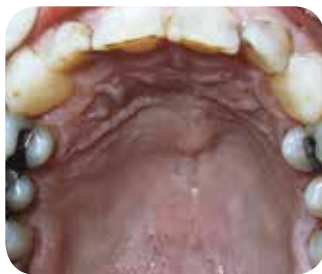Acute Apical Abscess



PostOp



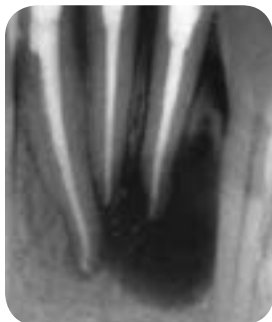24 mo. Recall



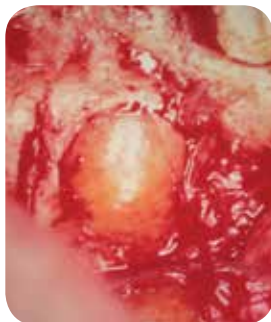Swelling Healed

**Case Two**

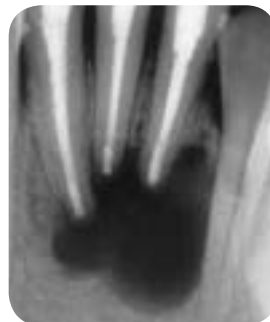Non-healing endodontic lesion involving teeth #23, 24 and 25. Biopsy revealed lesion was a periodontal cyst with mucinous metaplasia. Super-EBA retrofillings were placed in each tooth.



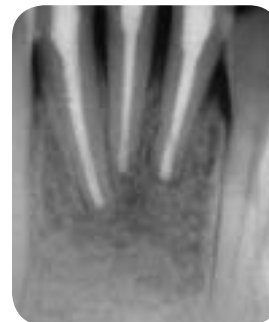PreOp



Cyst



PostOp



28 mo. Recall

TREATMENT CONSIDERATIONS/PROGNOSIS > **Apical Periodontitis**

The presence of periapical radiolucency is not an absolute indicator of a poor long-term prognosis. The vast majority of teeth with apical periodontitis can be expected to heal after nonsurgical or surgical endodontic treatment. Data indicate the presence of a lesion prior to treatment only decreases the prognosis slightly.

**FAVORABLE:**

- Pulp necrosis with or without a lesion present that responds to non-surgical treatment

**QUESTIONABLE:**

- Pulp necrosis and a periapical lesion is present that does not respond to nonsurgical root canal treatment but can be treated surgically

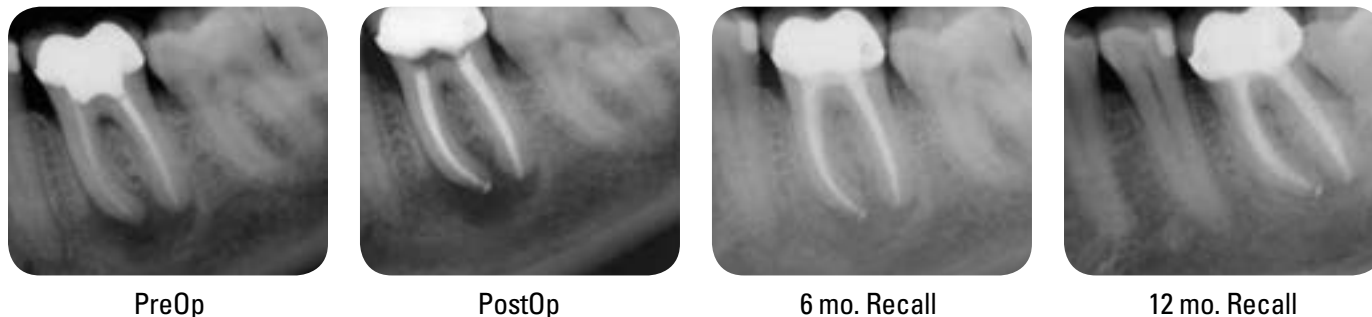
**UNFAVORABLE:**

- Pulp necrosis and a periapical lesion is present that does not respond to nonsurgical root canal treatment or subsequent surgical intervention



**Nonsurgical Root Canal Retreatment: Missed Canal**

Tooth #19 demonstrating poor obturation and a missed mesial canal.



TREATMENT CONSIDERATIONS/PROGNOSIS > **Nonsurgical Root Canal Retreatment: Missed Canal**

**FAVORABLE:**

- The etiology for failure of the initial treatment can be identified
- Nonsurgical endodontic retreatment will correct the deficiency

**QUESTIONABLE:**

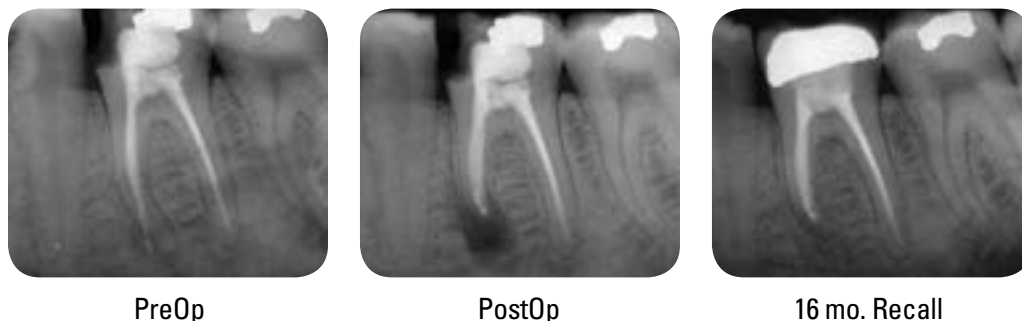- The etiology for failure of the initial treatment cannot be identified
- Nonsurgical endodontic retreatment may not correct the deficiency

**UNFAVORABLE:**

- The etiology for failure of the initial treatment cannot be identified and corrected with nonsurgical retreatment and surgical treatment is not an option

**Surgical Root Canal Treatment: Altered Anatomy**

Surgical treatment of tooth #19 to correct apical transportation in the mesial root.



TREATMENT CONSIDERATIONS/PROGNOSIS > **Surgical Root Canal Treatment: Altered Anatomy**  
(*e.g.*, loss of length, ledges, apical transportation)

**FAVORABLE:**

- The procedural complication can be corrected with nonsurgical treatment, retreatment or apical surgery

**QUESTIONABLE:**

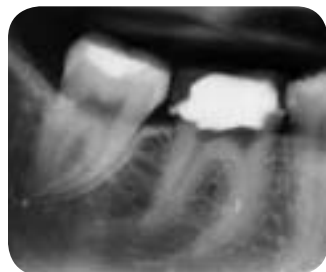- Canals debrided and obturated to the procedural complication, there is no apical pathosis and the patient is followed on recall examination

**UNFAVORABLE:**

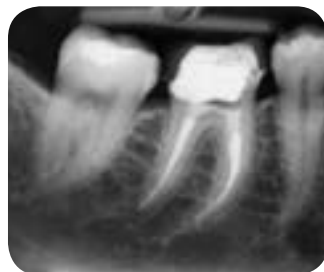- The patient is symptomatic or a lesion persists and the procedural complication cannot be corrected and the tooth is not amenable to surgery (apicoectomy/intentional replantation)

**Separated Instrument Case One**

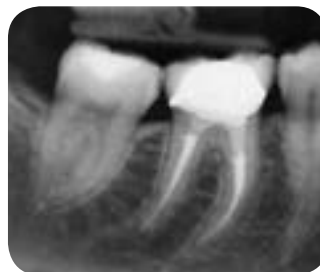Tooth #30 exhibiting a fractured instrument in the mesial root; recall examination demonstrates a successful outcome.



PreOp



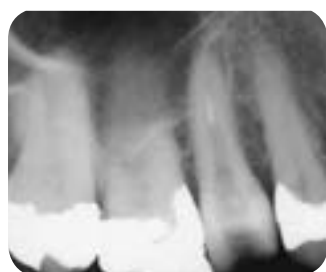PostOp



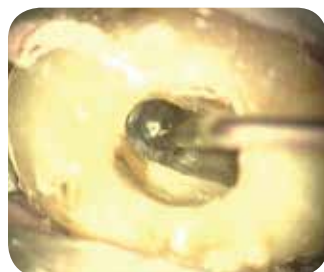24 mo. Recall

**Separated Instrument Case Two**

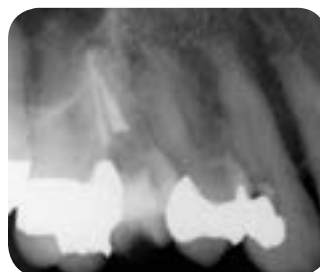Separated NiTi rotary instrument in palatal canal of tooth #4. Removed file with ultrasonics and copious irrigation; obturated with gutta-percha and AH Plus® sealer.



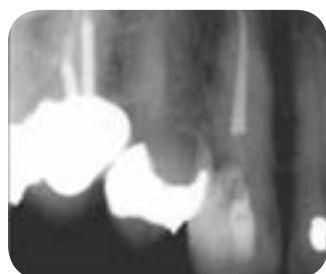PreOp



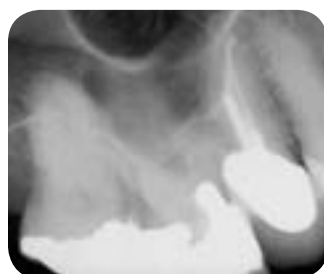Separated Instrument



PostOp



12 mo. Recall



24 mo. Recall

TREATMENT CONSIDERATIONS/PROGNOSIS > **Separated Instruments**

**FAVORABLE:**

- No periapical periodontitis
- In general, cases that have a separated instrument in the apical one-third of the root have favorable outcomes
- Able to retrieve nonsurgically or surgically if periapical pathosis is present
- Defect correctable with apical surgery

**QUESTIONABLE:**

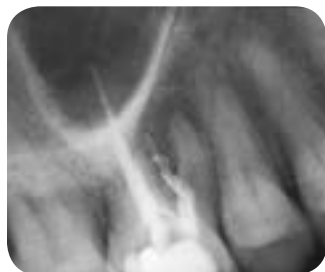- Instruments fractured in the coronal or mid-root portion of the canal and cannot be retrieved
- Patient asymptomatic
- No periapical periodontitis

**UNFAVORABLE:**

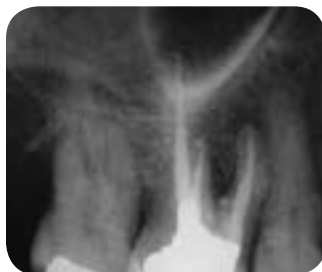- The patient is symptomatic or a lesion persists requiring extensive procedures in order to retrieve instrument that would ultimately compromise long-term survival of the tooth and surgical treatment is not an option (apicoectomy/intentional replantation)

**Perforations Case One**

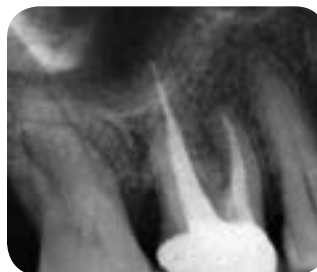Tooth #3 exhibiting a coronal perforation. Repaired with MTA in conjunction with nonsurgical root canal treatment.



PreOp



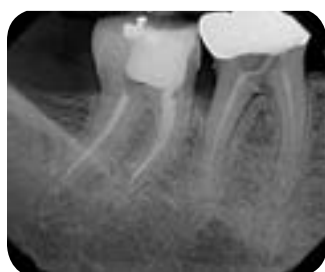PostOp



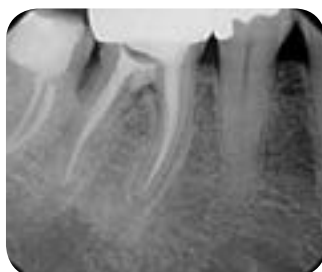36 mo. Recall

**Perforations Case Two**

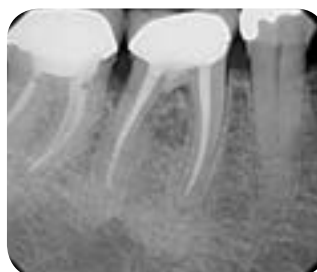Tooth #30 with previous retreatment attempt resulting in furcal perforation. Retreatment performed using interim calcium hydroxide and furcal perforation repaired with MTA.



PreOp



PostOp



12 mo. Recall

TREATMENT CONSIDERATIONS/PROGNOSIS > **Perforations-Location**

**FAVORABLE:**

- Apical with no sulcular communication or osseous defect

**QUESTIONABLE:**

- Mid-root or furcal with no sulcular communication or osseous defect

**UNFAVORABLE:**

- Apical, crestal or furcal with sulcular communication and a probing defect with osseous destruction

TREATMENT CONSIDERATIONS/PROGNOSIS > **Perforations-Time of Repair**

**FAVORABLE:**

- Immediate repair

**QUESTIONABLE:**

- Delayed repair

**UNFAVORABLE:**

- No repair or gross extrusion of the repair materials

TREATMENT CONSIDERATIONS/PROGNOSIS > **Perforations-Size**

**FAVORABLE:**

- Small (relative to tooth and location)

**QUESTIONABLE:**

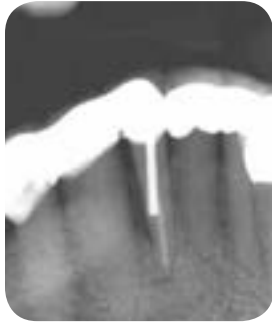- Medium

**UNFAVORABLE:**

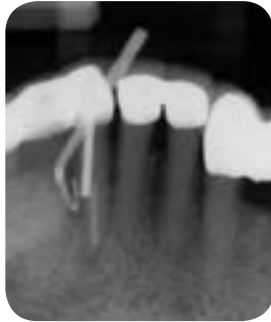- Large

**Post Perforations Case One**

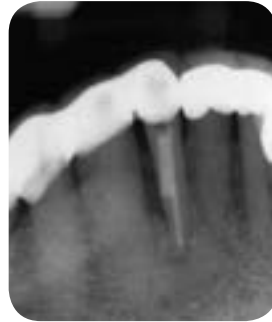Tooth #27 with sinus tract that traced to apical extent of post (no abnormal probings). Orthograde repair performed with MTA.



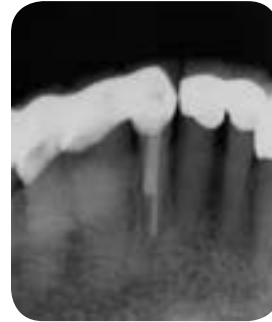PreOp



Sinus Tract Tracing



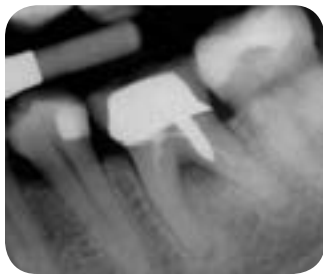PostOp



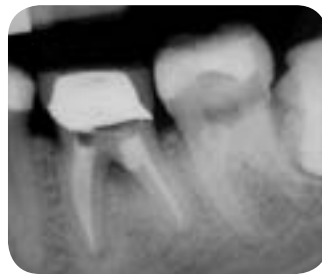12 mo. Recall

**Post Perforations Case Two**

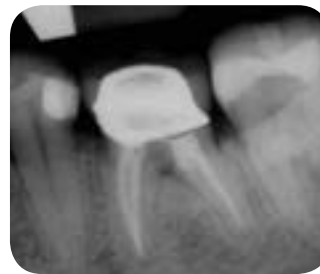Tooth #30 post perforation with screw post previously treated with paste obturation. Perforation repaired with MTA and tooth retreated.



PreOp



PostOp



12 mo. Recall

TREATMENT CONSIDERATIONS/PROGNOSIS > **Post Perforation**

**FAVORABLE:**

- No sulcular communication or osseous destruction

**QUESTIONABLE:**

- No sulcular communication but osseous destruction is evident
- The perforation can be repaired surgically

**UNFAVORABLE:**

- Long standing with sulcular communication, a probing defect and osseous destruction

TREATMENT CONSIDERATIONS/PROGNOSIS > **Strip Perforation**

**FAVORABLE:**

- Small with no sulcular communication

**QUESTIONABLE:**

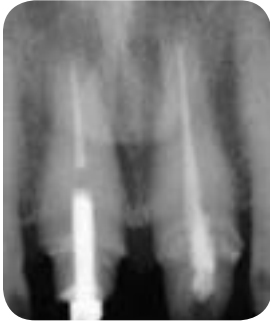- No sulcular communication and osseous destruction that can be managed with internal repair or surgical intervention

**UNFAVORABLE:**

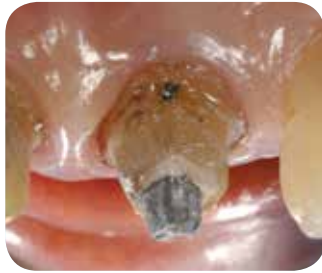- Sulcular communication and osseous destruction that cannot be managed with internal repair or surgical intervention

**Post Removal Case One**


Tooth #8 requiring removal of a prefabricated post.



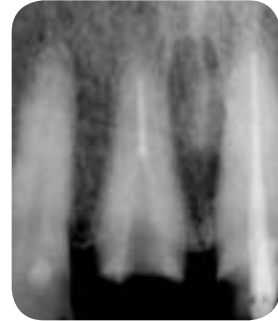PreOp



Clinical View



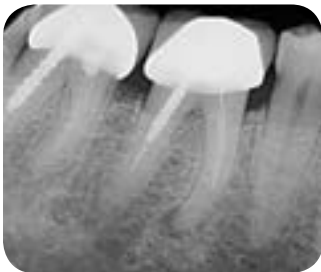Clinical View



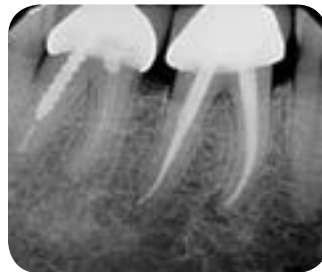PostOp

**Post Removal Case Two**

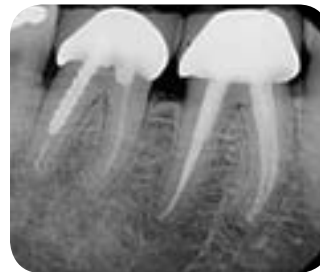Tooth #30 demonstrating incomplete paste obturation with threaded post and bonded resin core.



PreOp



PostOp



12 mo. Recall

TREATMENT CONSIDERATIONS/PROGNOSIS > **Posts**

With the use of modern endodontic techniques, most posts can be retrieved with minimal damage to the tooth and root. Ceramic posts, fiber posts, threaded posts, cast posts and cores, and prefabricated posts placed with resins are most challenging to remove. In some instances the post may not have to be removed and the problem can be resolved by performing root-end surgery (apicoectomy).

**FAVORABLE:**

- Prefabricated cylindrical stainless steel posts placed with traditional luting cements such as zinc phosphate

**QUESTIONABLE:**

- Cast post and cores placed with traditional luting cements such as zinc phosphate

**UNFAVORABLE:**

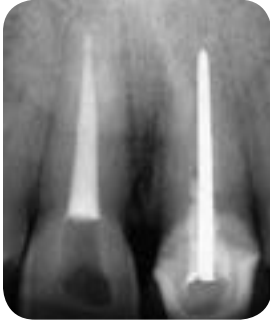- Prefabricated posts (stainless steel or titanium), cast post and cores placed with bonded resins; threaded, fiber and ceramic posts that cannot be removed or removal compromises the remaining tooth structure
- Teeth that cannot be retreated or treated surgically



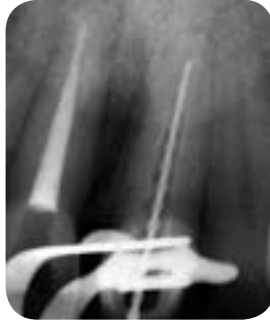

**Silver Point Retreatment Case One**

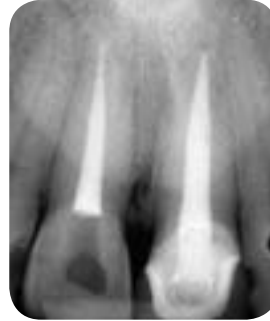Tooth #9 treated 25 years ago requiring retreatment.



PreOp



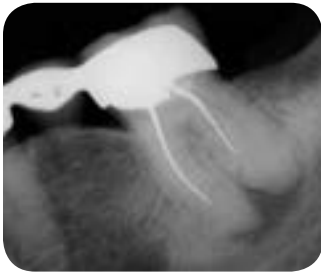
Working Length



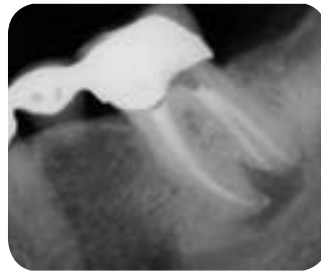
PostOp

**Silver Point Retreatment Case Two**

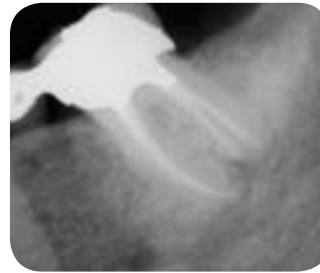Tooth #18 previously treated with silver points, filled short. Calcium hydroxide placed for two weeks.



PreOp



PostOp



24 mo. Recall

TREATMENT CONSIDERATIONS/PROGNOSIS > **Silver Points**

Silver points were a popular core obturation material in the 1960s and early 1970s. While their stiffness made placement and length control an advantage, the material did not fill the canal in three dimensions resulting in leakage and subsequent corrosion.

**FAVORABLE:**

- Silver cones that extend into the chamber facilitating retrieval and have been cemented with a zinc-oxide eugenol sealer

**QUESTIONABLE:**

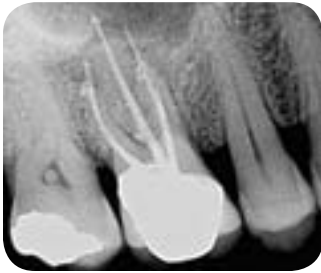- Silver cones that are resected at the level of the canal orifice or have been cemented with zinc phosphate or polycarboxylate cement
- Silver cones that can be bypassed or teeth that can be treated surgically

**UNFAVORABLE:**

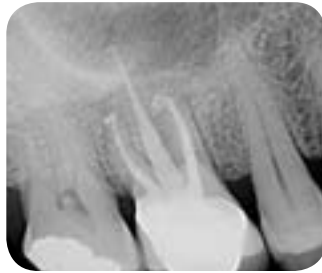- Sectional silver cones placed apically in the root to permit placement of a post that cannot be retrieved or bypassed and the tooth is not a candidate for surgical intervention

**Carrier-Based Systems**

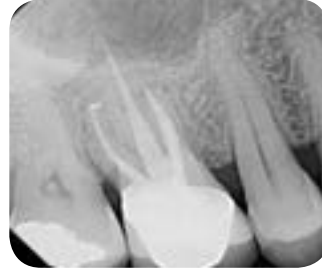Tooth #3 demonstrating overextended carrier-based obturation.



PreOp



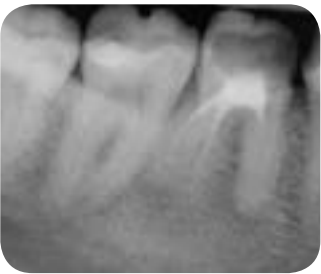PostOp



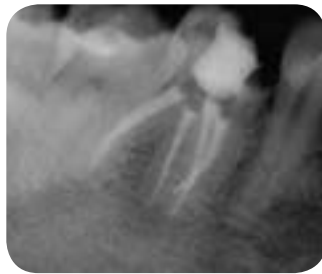12 mo. Recall

**Paste Retreatment**

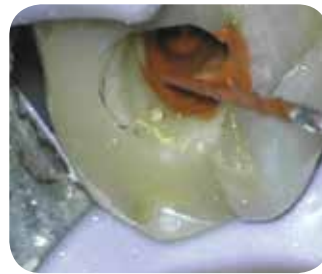Tooth #30 demonstrating resorcinol-formaldehyde resin-based obturation. Retreatment carried out using interim calcium hydroxide.



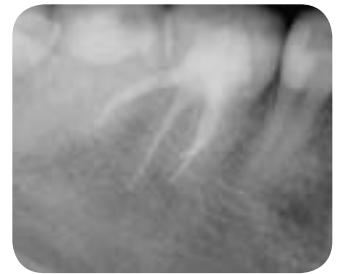PreOp



PostOp



Resorcinol Paste



12 mo. Recall

TREATMENT CONSIDERATIONS/PROGNOSIS > **Carrier-Based Systems/Pastes**

**Carrier-Based Systems**

Carrier-based thermoplastic (e.g., Thermafil®) systems are similar to silver cones. Historically, the core material was metal, later replaced with plastic. Current technology includes cross-linked gutta-percha. They can generally be removed as the gutta-percha can be softened with heat and solvents facilitating removal.

**Pastes**

With the use of modern endodontic techniques most filling materials can be retrieved with minimal damage to the tooth and root.

**FAVORABLE:**

- Soft or soluble pastes, pastes in the chamber and coronal one-third of the root that are removed easily
- Plastic carrier-based thermoplastic obturators

**QUESTIONABLE:**

- Hard insoluble pastes in the chamber extending into the middle-third of the root

**UNFAVORABLE:**

- Hard insoluble pastes placed into the apical one-third of the root that cannot be retrieved and the tooth is not amenable to surgical intervention (apicoectomy/intentional replantation)

*Treatment Options for the Compromised Tooth:*

*A Decision Guide* features different cases where the tooth has been compromised in both nonendodontically treated teeth and previously endodontically treated teeth. Based on the unique individualized features of each case and patient, there are key considerations in establishing a preoperative prognosis of Favorable, Questionable or Unfavorable. The photographs and radiographs in this guide illustrate favorable outcomes for our patients.

If your patient's condition falls into a category other than Favorable, referral to an endodontist, who has expertise on alternate treatment options that might preserve the natural dentition, is recommended. If the prognosis of the tooth is categorized as Questionable/Unfavorable in multiple areas of evaluation, extraction should be considered after appropriate consultation with a specialist.

In making treatment planning decisions, the clinician also should consider additional factors including local and systemic case-specific issues, economics, the patient's desires and needs, aesthetics, potential adverse outcomes, ethical factors, history of bisphosphonate use and/or radiation therapy.

Although the treatment planning process is complex and new information is still emerging, it is clear that appropriate treatment must be based on the patient's best interests.



American Association of Endodontists

211 E. Chicago Ave., Suite 1100  
Chicago, IL 60611-2691

Phone: 800/872-3636 (North America) or 312/266-7255 (International)  
Fax: 866/451-9020 (North America) or 312/266-9867 (International)

Email: [info@aae.org](mailto:info@aae.org) Website: [www.aae.org](http://www.aae.org)



[www.facebook.com/endodontists](http://www.facebook.com/endodontists)



@aaenews | @savingyourteeth



[www.youtube.com/rootcanalspecialists](http://www.youtube.com/rootcanalspecialists)